

BACCAUREA ANGULATA FRUIT JUICE PROTECTS RABBIT'S LIVER FROM HYPERCHOLESTEROLEMIA-INDUCED INJURY

Idris Adewale Ahmed^{1,3}, Maryam Abimbola Mikail^{2,3}, Muhammad Ibrahim³

¹Department of Biotechnology, Lincoln University College, Malaysia

²Department of Biomedical Science, Lincoln University College, Malaysia

³Department of Nutrition Sciences, International Islamic University Malaysia

*Corresponding Authors' Email: ahmedris1400@gmail.com/idrisahmed@lincoln.edu.my

ABSTRACT

Non-alcoholic fatty liver disease (NAFLD) is a clinicopathological syndrome strongly associated with hyperlipidemia, hypertriglyceridemia, insulin resistance and obesity. The objective of this study is to evaluate the potential health benefits of *Baccaurea angulata* fruit in preventing liver damage due to hypercholesterolemia. Twenty-five healthy adult New Zealand White rabbits were assigned to five groups for 90 days diet and intervention plan. While four groups (atherogenic groups) were fed 1% cholesterol diet and 0, 0.5, 1.0, and 1.5 mL of *B. angulata* juice kg/per day, the fifth group (negative control) was fed with commercial rabbit pellet only. After overnight fasting and sacrifice, the thoracic cavity was opened and the liver was carefully removed, specifically observing for any presence of a gross lesion and then immediately fixing in 4% paraformaldehyde for at least 48 hours for histopathological analysis. The hepatoprotective effect of *B. angulata* fruit juice was evident in the histological examination of liver tissues. The results indicate the potential health benefits of the antioxidant-rich *B. angulata* fruit juice as a functional food with a therapeutic effect against hypercholesterolemia-induced liver injury.

Keywords: Atherosclerosis, *B. angulata*, Hypercholesterolemia, Non-alcoholic fatty liver disease

INTRODUCTION

Non-alcoholic fatty liver disease (NAFLD) is the most common hepatic component of the metabolic syndrome as well as an independent risk factor for cardiovascular disease [CVD] (Targher *et al.*, 2005; Mikolasevic *et al.*, 2014). NAFLD is defined as the accumulation of liver fat >5% per liver weight, in the absence of excessive alcohol consumption. It refers to a wide spectrum of liver damage such as simple steatosis, steatohepatitis, advanced fibrosis and cirrhosis (Misra, Khashab & Chalasani, 2009). NAFLD is also a clinicopathological syndrome strongly associated with hyperlipidemia, hypertriglyceridemia, insulin resistance and obesity, among others (Targher, 2007). Undiagnosed NAFLD may also progress silently and result in cirrhosis, portal hypertension and liver-related death in early adulthood. Other possible explanations of mechanisms of the association of CVD with NAFLD include, but are not limited to, acceleration of the progression of insulin resistance, dyslipidemia and atherosclerosis, carotid atherosclerosis endothelial dysfunction, inflammation and oxidative stress as well as low levels of adiponectin (Ahmed, Barakat & Almobarak, 2012).

On the other hand, different kinds of antioxidant compounds such as carotenoids, flavonoids, phenolic acids and vitamins contained in fruits and vegetables,

are highly beneficial to human health by reducing the risk of degenerative diseases with no toxicity or other side effects (Ahmed, Mikail & Ibrahim, 2017; Ibrahim *et al.*, 2017a; Ibrahim *et al.*, 2017b).

Malaysia, especially, the region of Peninsular Malaysia, Sabah and Sarawak, has a very rich biodiversity of many indigenous fruits and vegetables growing wild. These nutritious fruits and medicinal plants are constantly exposed to 6-8 hours of daily sunlight throughout the year (Ibrahim *et al.*, 2013a). Therefore, tropical fruits in Malaysia are rich in antioxidants. Some of these fruits are commonly consumed by the locals but are yet to be thoroughly investigated by researchers in terms of their nutritional as well as health benefits

One of such fruits is *Baccaurea angulata* which are locally referred to as 'belimbing dayak' or 'belimbing hutan'. *B. angulata* belongs to the Euphorbiaceae (now, Phyllanthaceae) family. The profusely branched tree is about 8-10 m tall. It has thick and broad leaves, which are elliptical in shape. This fruit, red to purple in color, is seasonal and grows on stems and branches of the tree (Ibrahim *et al.*, 2013a; Ibrahim *et al.*, 2013b). The objective of the study was thus to evaluate the potential health benefits of *B. angulata* fruit juice in preventing liver damage due to hypercholesterolemia.

MATERIAL AND METHODS

Experimental Animal Design

The animal handling procedure and experimental protocols were approved by the International Islamic University Malaysia (IIUM) Research Ethics Committee (IREC), Kulliyyah of Medicine, IIUM, Kuantan Campus (ID NO.: IREC 04, Meeting No. 4/2012), and conformed to the guidelines of the Malaysian Code of Practice for the Care and Use of Animal for Scientific Purposes. Twenty-five healthy male adult rabbits (*Oryctolagus cuniculus*; New Zealand White strain), with body weight of 2300–2800 g, were obtained from A-Sapphire Enterprise, Sri Kembangan, Selangor, Malaysia, and were housed separately in cages in an air-conditioned room, at a temperature of 20±2°C, with a 12-h light/dark cycle and relative humidity of 50–60%.

Following one-month acclimatization period, the rabbits were randomly assigned to five groups (Table 1). Four groups (atherogenic groups) were fed cholesterol diet (1% cholesterol) and 0, 0.5, 1.0 or 1.5 mL of juice per kg/day, while the fifth group (negative control) was fed with commercial rabbit pellet for 90 days. The fruit juice was freshly-prepared daily and administered using a clean syringe. Clean potable water was allowed ad libitum and 120 g/day of food was provided during the experimental periods.

Table 1: Experimental design of the hypercholesterolemic rabbit study

Group (n=5)	Composition	Designation
Positive Control	1% cholesterol diet (Untreated)	PC
Low Dose	1% cholesterol diet + 0.5 mL/kg/day BA juice	LD
Medium Dose	1% cholesterol diet + 1.0 mL/kg/day BA juice	MD
High Dose	1% cholesterol diet + 1.5 mL/kg/day BA juice	HD
Negative Control	Commercial rabbit pellet (Untreated)	NgC

Organ Harvesting and Histopathological Analysis

After overnight fasting, the rabbits were humanely sacrificed after the expiration of the experimental period (90 days). The thoracic cavity was opened. The liver was carefully removed, washed three times with ice-cold sterile physiologic phosphate buffered saline (PBS), and gently blotted on clean filter paper. The livers were specifically observed for any presence of a gross lesion

and then immediately fixed in 4% paraformaldehyde in 0.1 M PBS (pH 7.4) for at least 48 hours for histopathological analysis. Grossing was carried out to take a small portion of the organ. Then, they were put into tissue cassette for tissue processing. The properly fixed liver tissues were processed and dehydrated gradually in a graded series of ethanol, using an automatic tissue processor, Leica TP 1020 (Leica Microsystem, Germany), then clarified in xylene and embedded in the wax (Leica EG 1160, Leica Microsystem, Germany) to make blocks for sectioning. Trimming and serial sectioning (3-5 sections/tissue) of tissue blocks into 5 µm thick ribbon were done by using a semi-auto rotatory microtome (Leica RM 2245, Leica Microsystem, Germany), and mounted onto super-frost Plus microscope slides (Fisher Scientific). Then, the microscope slides were dried on a hot plate at 52°C and kept in an oven overnight at 37°C prior to staining

Hematoxylin and Eosin Stainin

Hematoxylin and eosin (H&E) staining is a common stain for diagnosis purpose in histopathology. The H&E staining procedure was done manually according to the method from Bancroft and Gamble (2008) with slight modification. Stained slides were kept in a slide box for histological examination. Slides were viewed under a microscope (U-LH100HG, Olympus, USA), with an in-built camera attached to a monitor with analysis-LS Report software (Nikon, Tokyo, Japan).

RESULTS AND DISCUSSION

The approximate phytochemical composition of the BA whole fruit juice is shown in Table 2 based on 85% moisture content of the whole fruit (Ahmed *et al.*, 2013; Mikail *et al.*, 2013; Ahmed *et al.*, 2015).


Table 2: Approximate phytochemical composition of *B. angulata* fruit juice

Phytochemical Parameters	Value based on dry weight	Approximate value based on wet weight (juice)
TPC (mg CAT/kg)	4407.46±125.51	29383.07
TFC (mg QE/g)	28.23±0.84	188.20
TCC (mg BC/kg)	11.75±1.38	78.36
Ascorbic Acid (mg/kg)	449.18±4.79	2994.53
Caffeic Acid (mg/kg)	10.49±2.28	69.93
Carnosic Acid (mg/kg)	38.88±3.08	259.20
Catechin (mg/kg)	516.31±8.11	3442.07
Cinnamic Acid (mg/kg)	14.33±3.75	95.53
Myricetin (mg/kg)	27.34±2.54	182.27
Vanillic Acid (mg/kg)	92.72±4.61	618.13

Liver Morphology and Histopathology

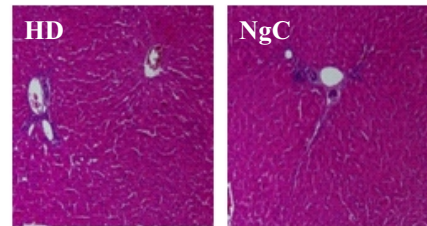
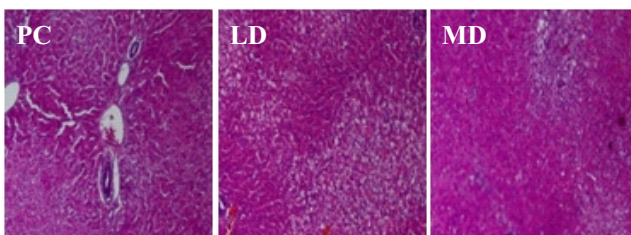
The gross comparison of livers showed an increased lipid deposition and apparent hepatic cholesterol toxicity in livers of all the atherogenic rabbits, compared to the negative control (Figure 1). The atherogenic rabbit showed an apparent paleness and rounded edges, which is consistent with a high lipid deposition in the Watanabe heritable hyperlipidemic (WHHL) rabbit strain (Suckow, Stevens and Wilson, 2012).

Figure 1: Gross comparisons of livers from (a) atherogenic and (b) negative control group.



Unhealthy fat organs are characterized by the enlargement of existing adipocytes, hampered adipogenic differentiation of the precursor cell (adipogenesis), extracellular matrix proteolysis, coordinated development of the tissue vascular network (angiogenesis), and adipose inflammation, among others (Ali *et al.*, 2013; Murdolo *et al.*, 2013; Serviddio, Bellanti and Vendemiale, 2013; Ibrahim *et al.*, 2017). The liver is majorly responsible for the removal of free fatty acids from the circulation through either catabolic oxidation to generate energy or anabolic synthesis of triglycerides by esterification and storage (Hasan *et al.*, 2014). In the present study, the examination of photomicrographs from liver sections stained with H&E stains showed the apparent presence of micro- and macro-vesicular hepatic steatosis and inflammation induced by a high-fat diet in high-cholesterol-fed rabbits, compared to the negative control group (Figure 2).

Figure 2: Examination of photomicrographs from liver sections stained with H&E stains



Note: PC= Positive control; LD, MD & HD are 0.5, 1.0 and 1.5 mL/kg/day atherogenic groups, respectively; and NgC= Negative control.

The supplementation of high-cholesterol diet with increasing doses of *B. angulata* fruit juice remarkably reduced the size and prevalence of lipid droplets in hepatocytes, and thus preserved the cellular integrity. The hepatoprotective effect of *B. angulata* fruit juice was evident in the histological examination of liver tissues. The micro-vesicular fats present throughout the liver in the high-cholesterol group were attenuated with increasing doses of *B. angulata* fruit juice. The results indicate the potential health benefits of the antioxidant-rich *B. angulata* fruit juice as a functional food, with a therapeutic effect against hypercholesterolemia-induced liver injury.

CONCLUSION

B. angulata fruit juice remarkably preserved the liver cells' integrity. *B. angulata* fruit could thus be described as hepatoprotective, hypocholesterolemic and anti-atherogenic. Further studies are suggested to elucidate the mechanisms of its actions.

REFERENCES

- Ahmed, I. A., Mikail, M. A. & Ibrahim, M. (2017). *Baccaurea angulata* fruit juice ameliorates altered hematological and biochemical biomarkers in diet-induced hypercholesterolemic rabbits. *Nutrition Research*, 42, pp 31-42.
- Ahmed, I. A., Mikail, M. A., Bin Ibrahim, M., Bin Hazali, N., Rasad, M. S. B. A., Ghani, R. A., Wahab, R. A., Arief, S. J. & Yahya, M. N. A. (2015). Antioxidant activity and phenolic profile of various morphological parts of underutilised *Baccaurea angulata* fruit. *Food Chemistry*, 172, pp 778-787.
- Ahmed, I. A., Mikail, M. A., Ibrahim, M., Hazali, N., Rasad, A., Baharii, M. S., Abdul Ghani, R., Abdul Wahab, R., Ichwan, A. & Jauhari, S. (2013). In vitro antioxidant properties of underutilized *Baccaurea angulata* fruit. *International Journal of Advances in*

- Agricultural & Environmental Engineering* (IJAE), 1(1), pp 144-150.
- Ahmed, M. H., Barakat, S. & Almobarak, A. O. (2012). Nonalcoholic fatty liver disease and cardiovascular disease: has the time come for cardiologists to be hepatologists? *Journal of obesity*, pp 1-9.
- Ali, A. T., Hochfeld, W. E., Myburgh, R. & Pepper, M. S. (2013). Adipocyte and adipogenesis. *European Journal of Cell Biology*, 92(6-7), pp 229-236.
- Bancroft, J. D. & Gamble, M. (2008). *Theory and practice of histological techniques*, 6th edition, Elsevier Health Sciences.
- Hasan, S., Zingg, J.-M., Kwan, P., Noble, T., Smith, D. & Meydani, M. (2014). Curcumin modulation of high fat diet-induced atherosclerosis and steatohepatosis in LDL receptor deficient mice. *Atherosclerosis*, 232(1), pp 40-51.
- Ibrahim, D., Hazali, N., Jauhari, N., Omar, M. N., Yahya, M. N. A., Ahmed, I. A., Mikail, M. A. & Ibrahim, M. (2013a). Physicochemical and antioxidant characteristics of *Baccaurea angulata* fruit juice extract. *African Journal of Biotechnology*, 12(34), pp 5333-5338.
- Ibrahim, D., Hazali, N., Jauhari, N., Yahya, M. N. A., Ahmed, I. A., Mikail, M. A. & Ibrahim, M. (2013b). Sub-chronic toxicological evaluation of the *Baccaurea angulata* (Belimbing Dayak) fruit juice in rats. *International Journal of Applied Research in Natural Products*, 6(4), pp 23-32.
- Ibrahim, M., Ahmed, I. A., Mikail, M. A., Ishola, A. A., Draman, S., Isa, M. L. M. & Yusof, A. M. (2017a). *Baccaurea angulata* fruit juice reduces atherosclerotic lesions in diet-induced Hypercholesterolemic rabbits. *Lipids in Health and Disease*, 16(1), pp 1-8.
- Ibrahim, M., Mikail, M. A., Ahmed, I. A., Hazali, N., Rasad, M. S. B. A., Ghani, R. A., Hashim, R., Arief, S. J., Isa, M. L. M. & Draman, S. (2017b). Comparison of the effects of three different *Baccaurea angulata* whole fruit juice doses on plasma, aorta and liver MDA levels, antioxidant enzymes and total antioxidant capacity. *European Journal of Nutrition*, pp 1-12.
- Mikail, M. A., Ahmed, I. A. & Bin Ibrahim, M. (2013). Changes in the markers of atherosclerosis following administration of Belimbing dayak (*Baccaurea angulata*) fruit juice in experimental rabbits fed with cholesterol diet. *International Journal of Advances in Agricultural & Environmental Engineering* (IJAE), 1(1), pp 151-154.
- Mikolasevic, I., Racki, S., Zaputovic, L., Lukenda, V., Milic, S. & Orlic, L. (2014). Nonalcoholic fatty liver disease (NAFLD): a new risk factor for adverse cardiovascular events in dialysis patients. *Medical Hypotheses*, 82(2), pp 205-208.
- Misra, V. L., Khashab, M. & Chalasani, N. (2009). Nonalcoholic fatty liver disease and cardiovascular risk. *Current Gastroenterology Reports*, 11(1), pp 50-55.
- Murdolo, G., Piroddi, M., Luchetti, F., Tortoioli, C., Canonico, B., Zerbinati, C., Galli, F. & Iuliano, L. (2013). Oxidative stress and lipid peroxidation by-products at the crossroad between adipose organ dysregulation and obesity-linked insulin resistance. *Biochimie*, 95(3), pp 585-594.
- Serviddio, G., Bellanti, F. & Vendemiale, G. (2013). Free radical biology for medicine: learning from nonalcoholic fatty liver disease. *Free Radical Biology and Medicine*, 65, pp 952-968.
- Suckow, M. A., Stevens, K. A. & Wilson, R. P. (2012). *The laboratory rabbit, guinea pig, hamster, and other rodents*, Academic Press, London, United Kingdom.
- Targher, G. (2007). Non-alcoholic fatty liver disease, the metabolic syndrome and the risk of cardiovascular disease: the plot thickens. *Diabetic Medicine*, 24(1), pp 1-6.
- Targher, G., Bertolini, L., Poli, F., Rodella, S., Scala, L., Tessari, R., Zenari, L. & Falezza, G. (2005). Nonalcoholic fatty liver disease and risk of future cardiovascular events among type 2 diabetic patients. *Diabetes*, 54(12), pp 3541-3546.